

## Fatal Puumala Hantavirus Disease: Involvement of Complement Activation and Vascular Leakage in the Pathobiology

Tarja Sironen,<sup>1</sup> Jussi Sane,<sup>1</sup> Marja-Liisa Lokki,<sup>1</sup> Seppo Meri,<sup>1</sup> Leif C. Andersson,<sup>1</sup> Timo Hautala,<sup>2</sup> Heikki Kauma,<sup>2</sup> Sakari Vuorinen,<sup>3</sup> Johan Rasmuson,<sup>4</sup> Magnus Evander,<sup>5</sup> Clas Ahlm,<sup>4</sup> and Antti Vaheeri<sup>1</sup>

<sup>1</sup>Medicum, University of Helsinki, Helsinki, Finland; <sup>2</sup>Department of Internal Medicine, Oulu University Hospital, Oulu, Finland; <sup>3</sup>Etelä-Savo Hospital District, Mikkeli, Finland; <sup>4</sup>Department of Clinical Microbiology, Infectious Diseases, Umeå University, Umeå, Sweden; <sup>5</sup>Department of Clinical Microbiology, Virology, Umeå University, Umeå, Sweden

The case-fatality rate of hantavirus disease depends strongly on the causative hantavirus, ranging from 0.1% to 40%. However, the pathogenesis is not fully understood, and at present no licensed therapies exist. We describe fatal cases caused by Puumala hantavirus indicating involvement of complement activation and vascular leakage.

**Keywords.** case-fatality rate; complement; hantavirus; Puumala virus; vascular leakage.

Hantaviruses are the causative agents of hemorrhagic fever with renal syndrome (HFRS) in Eurasia and hantavirus cardiopulmonary syndrome (HCPS) in the Americas. The case-fatality rate depends strongly on the hantavirus species, ranging from 0.1% in mild forms of HFRS to 40% in severe HCPS [1]. Puumala virus (PUUV) causes a mild form of HFRS, also denoted nephropathia epidemica (NE), common in Northern and Central Europe [2]. The hallmarks of the pathobiology of hantavirus diseases include vascular leakage of endothelial cells (increased capillary permeability), thrombocytopenia, and complement activation. Immunopathology includes certain cytokines (TNF- $\alpha$ , IL-6, and others) and activation of cytotoxic T cells and regulatory T cells [1–3]. PUUV-infected patients suffering from severe disease are more likely to exhibit a low titer of antibodies against PUUV [4]. Similarly, patients who later have a severe course of HCPS tend to have a low titer

of neutralizing antibodies against Sin Nombre virus at the time of hospital admission [5].

Endothelial cells are commonly infected by hantaviruses that, however, do not seem to be cytotoxic. Thus, the infection alone may not explain the increased permeability of endothelial cells. In addition, immunogenetic factors such as HLA and complement genes as well as cytokine polymorphisms, can affect the clinical course of hantavirus disease [6]. Capillary leakage is thought to be largely mediated by bradykinin (BK), a vasodilator nonapeptide generated locally in the vasculature from high-molecular weight kininogen by the kallikrein-kinin proteolytic system. BK is of special interest as its effects can be counteracted by the BK receptor blocker icatibant. It is a nontoxic drug that is used for the treatment of angioedema, a life-threatening condition where swelling can potentially obstruct the airways. Two severe PUUV patients with extensive capillary leakage leading to hypotonic shock, have been successfully treated with icatibant [2, 7].

Finland and Northern Sweden have the highest global incidence of HFRS; in Finland during recent years, 1000–3000 cases have been diagnosed annually [1, 2]. A few fatal cases have been described from these countries previously [8–10]. In Sweden, of the 5282 HFRS cases diagnosed in 1997–2007, 0.4% died within 3 months after diagnosis [11]. The clinical features of the Swedish cases 3 and 4 have been described previously [12], and we had the unique opportunity to further analyze the underlying pathogenic mechanisms of fatal cases from both Finland and Sweden. All 4 cases were diagnosed premortem as PUUV infections by serology.

### PATIENTS

#### Case 1 (Eastern Central Finland)

The patient was a previously healthy 37-year-old male with a history of smoking. He died of severe PUUV infection on day 4 after the onset of high fever, vomiting and diarrhea, headache, and visual disturbances. The condition deteriorated quickly, and the patient developed hypotonia and multi-organ failure. The patient had respiratory distress, tachycardia, pleural fluid, hemoconcentration, acute kidney failure (creatinine 224  $\mu$ mol/L), liver failure (P-ALP 619–839 U/L), C-reactive protein of 113 mg/L, and severe thrombocytopenia. Of the complement components, circulating C3 was low, C4 was normal, and SC5b-9 was strongly elevated. The infecting PUUV variant was sequenced completely, and high viral loads were reported in the lung and kidney tissues [13].

In autopsy, the main findings were punctate hemorrhages in most tissues, severe edema, and ascites. Necrosis was found in the liver and hypophysis and the lungs showed signs of acute respiratory distress syndrome, while kidneys were macroscopically normal. Hematoxylin and eosin staining showed severe pathology in the lungs, heart, spleen, liver, and hypophysis. PUUV

Received 30 August 2017; editorial decision 13 October 2017; accepted 19 October 2017.

Correspondence: T. Sironen, PhD, Department of Virology, Faculty of Medicine, University of Helsinki, Haartmaninkatu 3, FIN-00014 Helsinki, Finland ([tarja.sironen@helsinki.fi](mailto:tarja.sironen@helsinki.fi)).

#### Open Forum Infectious Diseases®

© The Author 2017. Published by Oxford University Press on behalf of Infectious Diseases Society of America. This is an Open Access article distributed under the terms of the Creative Commons Attribution-NonCommercial-NoDerivs licence (<http://creativecommons.org/licenses/by-nc-nd/4.0/>), which permits non-commercial reproduction and distribution of the work, in any medium, provided the original work is not altered or transformed in any way, and that the work is properly cited. For commercial re-use, please contact [journals.permissions@oup.com](mailto:journals.permissions@oup.com).

DOI: 10.1093/ofid/ofx229

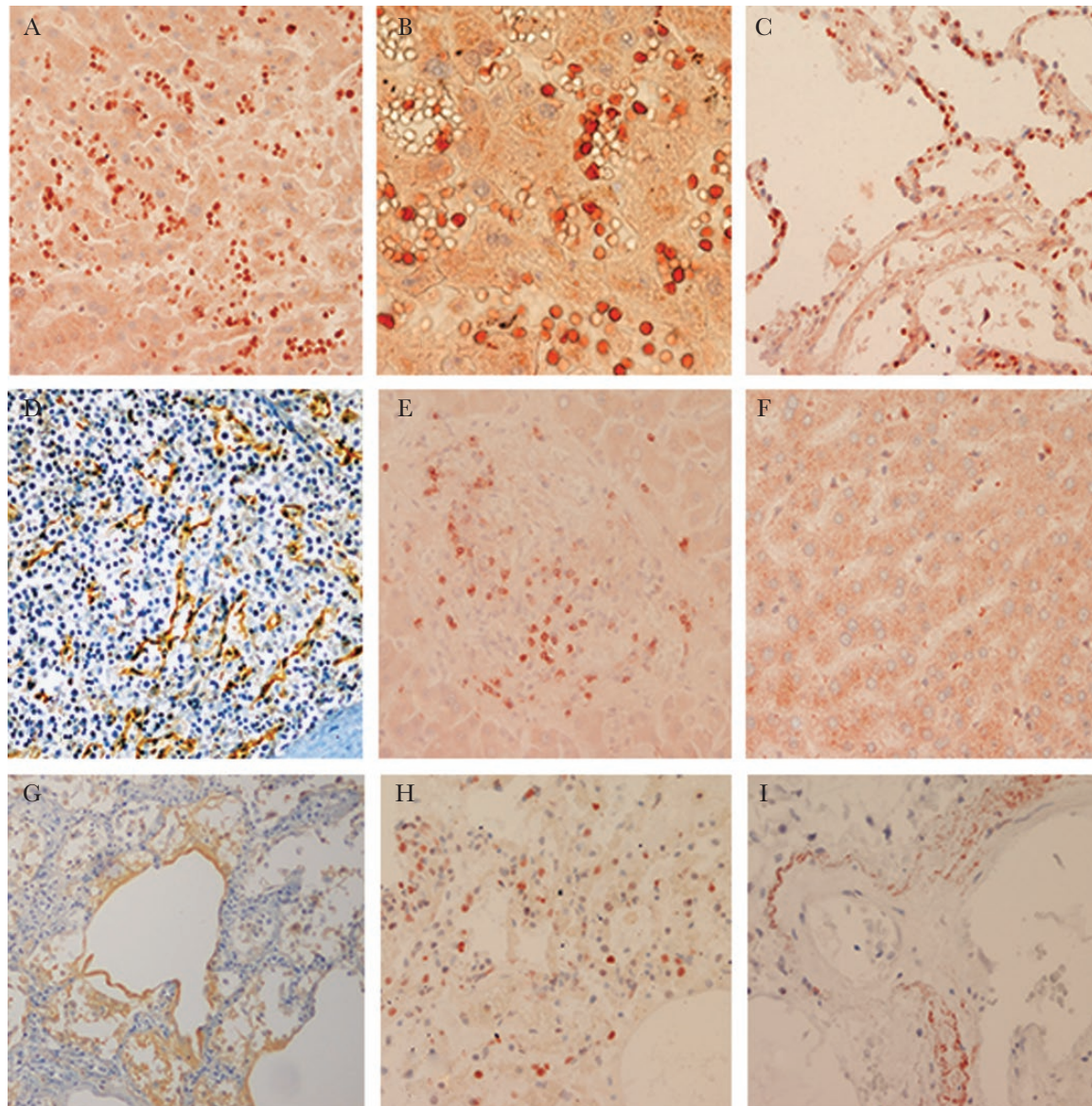
nucleocapsid protein (N) was detected in a few cells in hypophysis, brain endothelial cells, in liver sinusoids in the kidneys and lungs, and very strongly in the spleen endothelial cells (Figure 1d). The spleen showed hemorrhages and congestion. CD3-positive T-cell infiltrates were most apparent in the liver, but the staining was clearly positive also in the lungs and spleen. Complement SC5b-9 and C3d deposits were strongest in the lungs (Figure 1g) and hypophysis, and focally also in the liver and kidneys.

The patient had the risk genes HLA-B\*08 and HLA-DRB1\*03 most likely as a haplotype. Complement C4 gene numbers were 1 C4A gene and 2 C4B genes by genomic real-time polymerase

chain reaction (RT-PCR) corresponding to the strong association of C4A deficiency with the haplotype B\*08, DRB1\*03 [6]. The C4 genotype of Case 1 was confirmed by C4 phenotyping.

#### Case 2 (Northern Finland)

The patient was a 58-year-old male farmer with previous hypertension who developed typical signs of PUUV infection including blurred vision (acute myopia), oliguria, and hypotension (93/55 mmHg). He died unexpectedly on the second day of hospitalization. In the autopsy, the patient's hypophysis was slightly enlarged and showed signs of hemorrhages and necrosis. PUUV



**Figure 1.** Immunohistological findings. Puumala hantavirus nucleocapsid antigen (stained with an anti-Puumala N Pab) in mononuclear leukocytes in liver sinusoids (a, b), in lung alveolar capillaries (c), in cells lining spleen sinusoids (d), and in CD8-positive (stained with an anti-CD8 Mab from Monosan) lymphocytes in a portal area of the liver (e). No positive staining for PUUV antigen in a control liver (f). In lungs, intra-alveolar staining of complement C3d (g) (stained with an anti-C3d Pab from Dako), complement activation product SC5b-9 (stained with an anti-SC5b-9 Mab from Quidel) in single cells (h), and in deposits in lung vessel walls. Magnifications: (a, c, d, e, f, h, i) 200 $\times$ ; (b) 400 $\times$ ; (g) 100 $\times$ . (a–c and e–i) Detection by the fully automated Ventana Discovery Slide stainer with Ventana iViewDAB kit. (d) VectaStain ABC kit with Vector Red as substrate.



N was detected in the hypophysis (in endocrine and endothelial cells) as well as in the kidneys, lung, and spleen tissue samples. These aspects of Case 2 and of 2 NE patients who developed panhypopituitarism have been previously described [10].

We analyzed further the histology and the distribution of complement components. Lung tissues were also examined in more detail. The kidneys had acute proximal tubular necrosis with protein casts in collecting tubules and small hemorrhages in glomeruli. No inflammatory cell infiltrates were seen in the kidneys. The liver had lymphocyte infiltrates in portal areas and small necrotic foci in hepatic parenchyma. The liver, spleen, kidneys, and lungs had venous congestion. The heart was slightly hypertrophied, and the myocardium fibrotic. PUUV N antigen was found from the kidneys, spleen, and hypophysis. In addition, the lungs were also found to be RT-PCR-positive for PUUV RNA. The lungs showed strong local staining for SC5b-9, as well as strong local signal for C3d. The hypophysis was positive for SC5b-9, with only a few positive cells for C3c or C3d. The liver showed strong local signal for C3d in the blood vessel walls.

#### Case 3 (Northern Sweden)

A 73-year-old nonsmoking woman with a history of hypertension and type II diabetes was admitted to the intensive care unit due to fever, hypotension, and acute respiratory distress. Extensive pulmonary edema and bilateral pleural effusions indicative of thoracic vascular leakage were detected. She had fallen ill with malaise and fever the previous day. She developed hypotensive shock and multiple organ failure and eventually died after 13 days of hospital care. PUUV seroconversion occurred late during the first week of illness. Laboratory results also showed evidence of liver inflammation and cell damage, with markedly elevated liver transaminases and lactate dehydrogenase. The lungs were edematous and contained high numbers of alveolar macrophages (CD68+), as well as inflammatory cell infiltrates, consisting mostly of CD8+ T cells, which were also found, for example, in the portal area of the liver (Figure 1e). As previously described [12], PUUV RNA could be detected in samples from the lungs by PCR, but PUUV antigen could not be visualized using a monoclonal antibody (A1C5) directed against the N antigen. Here, in contrast, using a polyclonal antibody, PUUV N antigen was indeed demonstrated in mononuclear leukocytes in liver sinusoids (Figure 1a, b) and lung alveolar capillaries (Figure 1c). Complement SC5b-9 deposits were strongest in the lungs (Figure 1h and i).

#### Case 4 (Northern Sweden)

A 63-year-old smoking male with a history of hypertension and mild chronic obstructive pulmonary disease was admitted to the intensive care unit due to acute respiratory distress, hypotension, and confusion. Three days prior, he had fallen ill with fever, chills, cough, and dyspnea. On admission, serology was PUUV IgM positive, IgG was negative, and PUUV RNA was detectable in plasma. The patient was intubated due to poor

oxygenation, and vasoactive drugs were started to maintain blood pressure. Despite this, the patient died in refractory circulatory shock after 2 days in hospital. Postmortem examination showed pulmonary edema indicating pulmonary vascular leakage and infiltrates of lymphocytes showing the same immunophenotype as in Case 3.

In summary, we observed severe pathology in the lungs, spleen, liver, and hypophysis, but the kidneys and brains were almost normal. The amount of virus did not correlate with the amount of CD3/CD8 or SC5b-9. CD3-positive infiltrates were most apparent in the liver, complement activation was strongest in the lungs and in the hypophysis, focal also in the liver, and punctate in the kidneys. PUUV amount was highest in the spleen.

## DISCUSSION

The previously documented fatal PUUV cases, 4 from Finland and 1 from Sweden [8–10] all had fever, hypotension, hemorrhages, thrombocytopenia, and proteinuria. Congestion or edema was reported in all but 1, who died within 3 days after onset of fever. These features may be explained by increased vascular leakage. Bradykinin is considered to be an essential effector of vascular leakage [2, 7]. In 2 reported cases of PUUV infection, capillary leakage was severe and the patients remained hypotonic (mean arterial pressure 50–60 mmHg) despite the massive fluid resuscitation but remained alive when treated with icatibant [2, 7].

We found premortem complement activation: normal C4, low C3, and high SC5b-9 levels. Autopsy revealed deposits of C3d and SC5b-9, especially in the lungs, to our knowledge for the first time. Notably, PUUV N was found in both Case 1 and Case 2 in the spleen, known to be commonly enlarged in NE. Previous studies have shown that complement activation in PUUV disease (low C3 and high SC5b-9 at the acute stage) correlates with clinical and laboratory parameters reflecting NE severity [2, 3]. All this suggests that it may be worth studying whether icatibant and eculizumab (a recombinant humanized monoclonal anti-C5 antibody preventing generation of the terminal complement complex C5b-9) are beneficial in the treatment of severe forms of hantaviral disease including HCPS. Furthermore, as the pathogenesis of other viral hemorrhagic fevers shows similarities to those described here, study of the role of complement activation might be of interest also in these diseases [14, 15].

## Acknowledgments

We thank Tiiu Arumäe, Sanna Mäki, Irina Suomalainen, and Anna Wilenius for expert technical assistance.

**Financial support.** This work was supported by Sigrid Jusélius Foundation, Finland, The Swedish Foundation for Strategic Research, and Magnus Ehnrooth foundation.

**Potential conflicts of interest.** All authors: no reported conflicts of interest.

All authors have submitted the ICMJE Form for Disclosure of Potential Conflicts of Interest. Conflicts that the editors consider relevant to the content of the manuscript have been disclosed.

## References

1. Vaehri A, Strandin T, Hepojoki J, et al. Uncovering the mysteries of hantavirus infections. *Nat Rev Microbiol* **2013**; 11:539–50.
2. Mustonen J, Mäkelä S, Outinen T, et al. The pathogenesis of nephropathia epidemica: new knowledge and unanswered questions. *Antiviral Res* **2013**; 100:589–604.
3. Sane J, Laine O, Mäkelä S, et al. Complement activation in Puumala hantavirus infection correlates with disease severity. *Ann Med* **2012**; 44:468–75.
4. Pettersson L, Thunberg T, Rocklöv J, et al. Viral load and humoral immune response in association with disease severity in Puumala hantavirus-infected patients—implications for treatment. *Clin Microbiol Infect* **2014**; 20:235–41.
5. Ye C, Prescott J, Nofchissey R, et al. Neutralizing antibodies and Sin Nombre virus RNA after recovery from hantavirus cardiopulmonary syndrome. *Emerg Infect Dis* **2004**; 10:478–82.
6. Charbonnel N, Pagès M, Sironen T, et al. Immunogenetic factors affecting susceptibility of humans and rodents to hantaviruses and the clinical course of hantaviral disease in humans. *Viruses* **2014**; 6:2214–41.
7. Vaehri A, Strandin T, Jääskeläinen AJ, et al. Pathophysiology of a severe case of Puumala hantavirus infection successfully treated with bradykinin receptor antagonist icatibant. *Antiviral Res* **2014**; 111:23–5.
8. Linderholm M, Settergren B, Ahlm C, et al. A Swedish fatal case of nephropathia epidemica. *Scand J Infect Dis* **1991**; 23:501–2.
9. Valtonen M, Kauppila M, Kotilainen P, et al. Four fatal cases of nephropathia epidemica. *Scand J Infect Dis* **1995**; 27:515–7.
10. Hautala T, Sironen T, Vapalahti O, et al. Hypophyseal hemorrhage and panhypopituitarism during Puumala virus infection: magnetic resonance imaging and detection of viral antigen in the hypophysis. *Clin Infect Dis* **2002**; 35:96–101.
11. Hjertqvist M, Klein SL, Ahlm C, Klingstrom J. Mortality rate patterns for hemorrhagic fever with renal syndrome caused by Puumala virus. *Emerg Infect Dis* **2010**; 16:1584–6.
12. Rasmuson J, Andersson C, Norrman E, et al. Time to revise the paradigm of hantavirus syndromes? Hantavirus pulmonary syndrome caused by European hantavirus. *Eur J Clin Microbiol Infect Dis* **2011**; 30:685–90.
13. Plyusnina A, Razzauti M, Sironen T, et al. Analysis of complete Puumala virus genome, Finland. *Emerg Infect Dis* **2012**; 18:2070–2.
14. Basler CF. Molecular pathogenesis of viral hemorrhagic fever. *Semin Immunopathol* **2017**; 39:551–61.
15. Paessler S, Walker DH. Pathogenesis of the viral hemorrhagic fevers. *Annu Rev Pathol* **2013**; 8:411–40.